

CHAPTER

---

# 47

## RAMPHASTIDAE

---

Hans Cornelissen  
Branson W. Ritchie

**T**he family Ramphastidae, included in the order Piciformes, consists of six genera divided into 43 species or subspecies (Table 47.1).<sup>15</sup>

These birds are indigenous to South America, ranging from southern Mexico to northern Argentina.<sup>15</sup> Of the 43 species of toucans, toucanets and aracarís, only a few are frequently seen in captivity, including the Toco, Keel-billed, Red-billed and Channel-billed Toucans, and the Green Aracari (rare). These birds have been maintained in captivity since the Spanish Conquistadors first landed in the Americas, but active breeding programs have occurred only during the past 30 years. The average longevity in captivity is 20 years.

The *Ramphastos* spp. most commonly encountered as companion birds are the Toco and Keel-billed Toucans. If hand-raised, these birds are tame, easily handled and highly inquisitive. These large, active birds require plenty of space for exercise and produce a voluminous, moist excrement, which may account for the low numbers of these birds that are maintained as pets.

## Anatomy

Toucans have a large, lightweight, highly vascular bill composed of spongy bone (Figure 47.1). Several branches of the fifth cranial nerve innervate the bill (Figure 47.2), which is extremely sensitive. Toucans have a long keratinous tongue with lateral horn fringes. These birds have no crop and have an intestinal tract that is shorter and wider than that found in Psittaciformes of similar size. There is no cecum. The gall bladder is elongated. Nestlings have a keratinous thickening on the caudal side of the intertarsal joints (heel pad), which falls off shortly after they leave the nest.<sup>31</sup> Ramphastids have a zygodactyl foot. The trachea deviates ventrally at the level of the thoracic inlet and should not be misinterpreted as pathology radiographically (Figure 47.3). A detailed description of the biomechanics of the skull and beak is available in the literature.<sup>18,19</sup>

### Gender Determination

Sexual dimorphism occurs in some Ramphastidae, while others are monomorphic and gender must be determined by endoscopy (Table 47.2).<sup>35</sup> Spot-billed Toucans have individually distinct beak patterns that can be photographed and used for identification.

In general, male Ramphastids have a larger beak than females. To determine the beak's length, the lower margin of the upper mandible is measured from the edge of the facial skin outward toward the tip. In Toco Toucans, the beak of the male is generally greater than 16 cm in length, while in the female the measurement is less than 15.5 cm.<sup>35</sup>

TABLE 47.1 The Family Ramphastidae

Genera	Characteristics
<i>Ramphastos</i>	Large, black toucans
<i>Andigena</i>	Mountain-ranging toucans
<i>Aulacorhynchus</i>	Green mountain toucanets
<i>Selenider</i>	Lowland toucanets
<i>Ballonius</i>	Lowland toucanets
<i>Pteroglossus</i>	Aracaris

TABLE 47.2 Gender Dimorphism

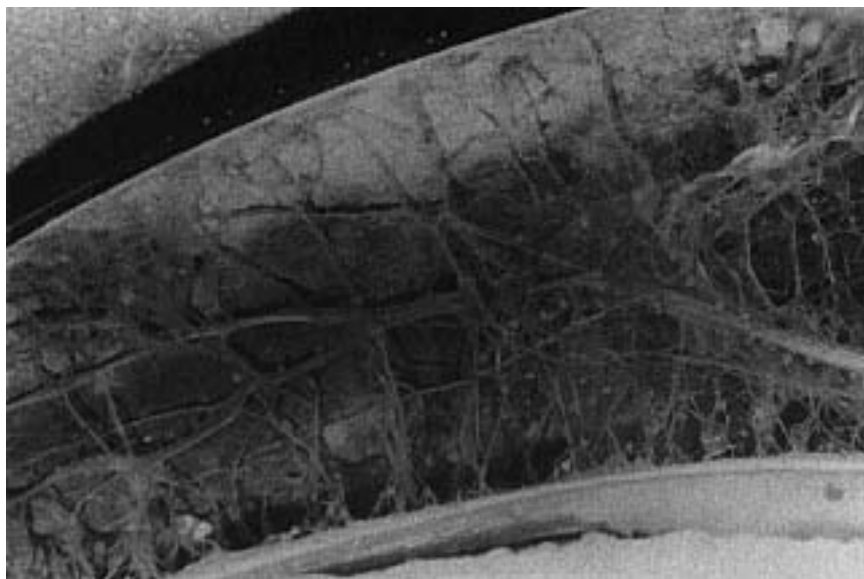
Genera	Male	Female
<i>Selenidera</i> sp.	Black head feathers	Brown head feathers
<i>S. culik</i>	Black neck and underparts	Chestnut neck, grey underparts
<i>Pteroglossus viridis</i>	Black head feathers	Brown head feathers
<i>P. inscriptus</i>	Black head feathers	Brown head feathers

## Behavior

Toucans can be loud and aggressive, particularly if untamed. Tame birds that are not given sufficient attention may also become very aggressive toward their keepers. Ramphastids are best restrained by initially removing them from the enclosure with a net or large towel. The bird can then be controlled by holding the beak in one hand and using a towel loosely wrapped around the body to control the wings and feet. Toucans should never be handled by the head and neck alone, as is commonly done with psittacine birds.

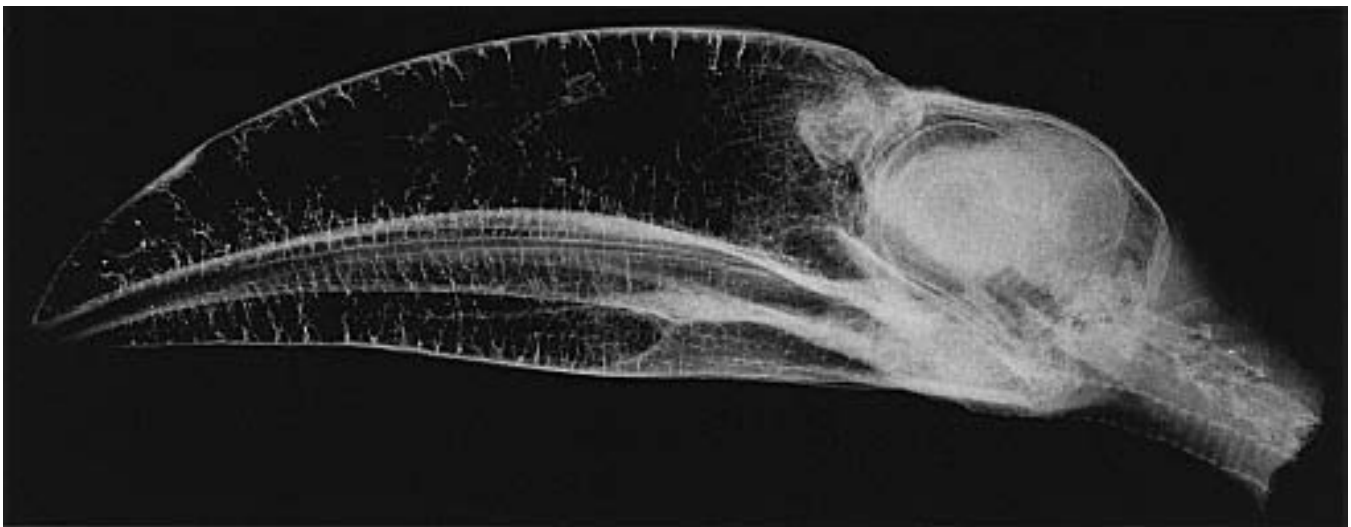

FIG 47.1 Radiograph of the head of a Channel-billed Toucan showing the massive bill composed of spongy bone. Note the large scleral ossicles that support the eyes (courtesy of Hans Cornelissen).



**FIG 47.2** Cross-section of the bill of a Channel-billed Toucan showing the extensive nerve supply to the extremely sensitive bill (courtesy of Hans Cornelissen).

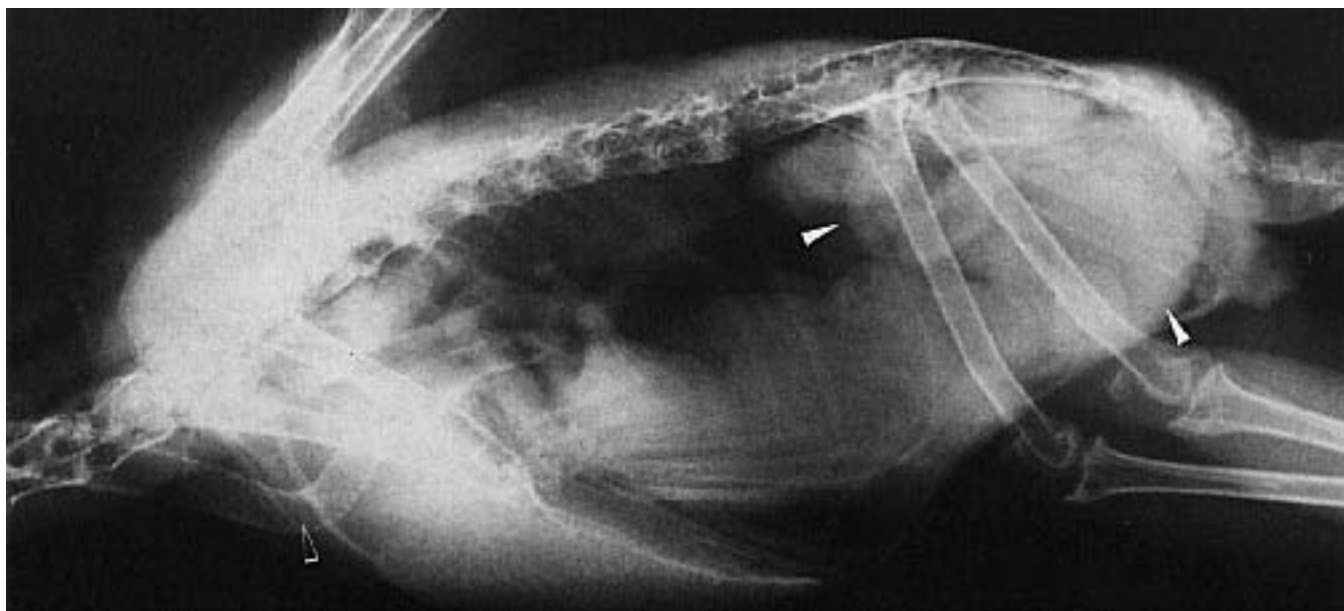
The active, curious nature of these birds often leads them to pick up and consume nonedible foreign bodies found in the enclosure (eg, rocks, pieces of wood, screws, string, coins). Resulting impactions can cause perforation or stasis of the gastrointestinal tract, which may lead to death. These birds are capable of being extremely destructive and can injure their beaks when biting on solid objects.

Ramphastids are known to sunbathe. This activity involves spreading the wings with their back to the sun. The mouth is usually open. However, these birds are extremely sensitive to heat prostration and must have access to shade at all times. When sleeping, these birds frequently place their bills into the feathers on the back and raise their tails to form a roof over the back and beak.

Toucans are active, inquisitive birds that are best housed as pairs in large flights with numerous, variably-sized perches. These birds are carnivorous, and if housed in mixed-species aviaries may consume smaller aviary inhabitants. If these birds must be mixed with other birds in the same flight, there should be sufficient room and adequate hiding places to ensure the safety of all inhabitants. Emerald Toucanets are particularly aggressive and should always be housed alone. Most male toucans are aggressively territorial and should not be housed with other males.

The aracarids are the most secretive of the Ramphastidae and require a nest box for security and privacy. This group can thrive if raised in species-specific

The aracarids are the most secretive of the Ramphastidae and require a nest box for security and privacy. This group can thrive if raised in species-specific



**FIG 47.3** A three-year-old Toco Toucan was presented with a progressive posterior paresis of four months' duration. Clinical pathology findings were unremarkable. Radiographs indicated enlarged kidneys. Necropsy findings included renal tubular necrosis and multifocal nonsuppurative neuritis. Note the normal ventral deviation of the trachea (open arrow) in the thoracic inlet. The normal bowel loops (arrows) of toucans appear distended when compared to those of similarly sized Psittaciformes.

colonies where the young from one clutch may assist the parents in caring for subsequent chicks.<sup>35</sup>

### ■ Husbandry

Free-ranging Ramphastids eat a variety of fruits, insects, spiders, bird eggs and small vertebrates.<sup>35</sup> They grasp the food with the tip of the bill, toss it into the air, catch the food in the open bill and swallow. Large food items are compressed with a foot and segmented into smaller pieces with the bill. An adequate maintenance diet for toucans would consist of fresh fruits (eg, melons, papaya, berries, tomatoes) supplemented with a low-iron, formulated diet.<sup>a-d</sup> Paprika may be added to the diet to maintain the bright coloration of the beak. During the breeding season, the diet should be supplemented with crickets (up to 800 per day when a pair is raising chicks), small mice and crushed hard-boiled eggs.<sup>34</sup> Fresh water for drinking and bathing should always be available. Toucans like to bathe and should be provided with large, easy-to-clean water containers.

The diet recommended for toucans is low in iron, which may reduce the chances of iron storage disease. The recommended level of iron for poultry is 40 to 60 ppm and the suggested diets for toucans approximate these levels. Many dog foods contain high levels of iron (up to 1500 ppm) and these high-iron foods should be avoided in a diet designed for Ramphastids. Grapes and raisins are also high in iron and should be avoided. Vitamin C enhances the absorption of iron, and citrus fruits should be offered on a limited basis.

The floor of a toucan enclosure should be well drained and easy to clean.<sup>4</sup> The large amount of moist foods that these birds consume results in the production of voluminous, malodorous excrement. These birds may normally pass some undigested food. Birds that are losing weight and consistently excreting undigested food should be evaluated.

### ■ Reproductive Characteristics

Toucans are best bred in large, planted flight enclosures with plenty of privacy. The walls of the enclosure should be covered with a cloth or plastic barrier to protect young chicks from collision injuries while they are learning to fly or, more appropriately, stop.

Toucans are cavity nesters. The larger species make an entrance hole in decayed portions of large trees. The smaller species take over the nests of woodpeck-

ers and remodel them for their own use. Most birds will readily accept natural palm logs as nesting cavities. Some toucans can be adapted to plywood boxes six feet long and one foot square with a concave bottom. The front can be covered with bark to simulate a natural nest. The nests of free-ranging birds can be found from a few inches to several feet below the entrance hole.

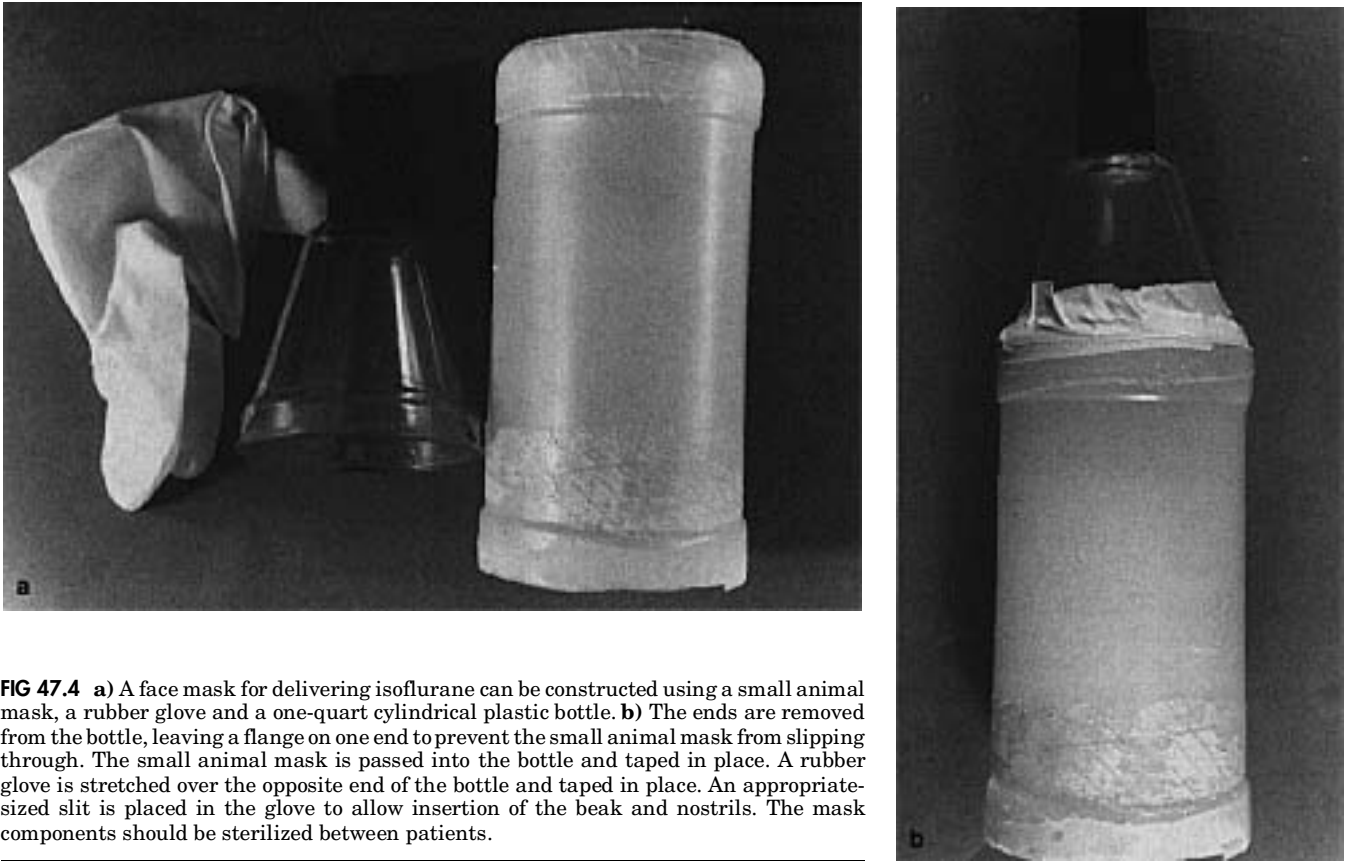
Courtship behavior is characterized by the males feeding the females, and both adults share incubation and rearing responsibilities. Sexual maturity generally occurs by three years of age.

Toco Toucans usually lay three to four eggs per clutch with an 18-day incubation period. Red-breasted Toucans usually have two to three eggs with a 16- to 17-day incubation period. Some of the toucans will use nesting material while others will empty the nesting cavity and lay the eggs directly on the bottom of the container.<sup>3a</sup> Frequently, the addition of nesting material will stimulate a pair to clean out the nest box and induce breeding.

Toucan chicks may leave the nest within 45 days of hatch and are generally weaned from two to four months of age.<sup>22</sup> Cannibalism of young chicks by the parents is common if the diet is not supplemented with crickets, mice or mealworms.

Toucan chicks have been successfully hand-raised from the egg. Initially, the diet consisted of small diced pieces of grape, banana, and pinkie mice soaked in water and offered by forceps. By three days of age, soaked monkey biscuit was added to the diet. The neonates were fed every two hours for the first twelve hours and then every three hours for 16 days, when the feeding frequency was reduced to four times per day. The eyes were open at three to four weeks of age. It is important to remember that these birds do not have a crop and should be fed smaller quantities and more frequently than psittacine neonates. Weaning may occur from two to four months of age.<sup>3a</sup> A neonate should be expected to gain weight daily and any weight loss is an indication of a problem. The weight should double each week.

Toucans can be anesthetized using isoflurane delivered through a modified face mask (Figure 47.4). Blood collection techniques are similar to those described for other avian species. Normal blood parameters are listed in the Appendix.<sup>33,34</sup>



**FIG 47.4** **a)** A face mask for delivering isoflurane can be constructed using a small animal mask, a rubber glove and a one-quart cylindrical plastic bottle. **b)** The ends are removed from the bottle, leaving a flange on one end to prevent the small animal mask from slipping through. The small animal mask is passed into the bottle and taped in place. A rubber glove is stretched over the opposite end of the bottle and taped in place. An appropriately sized slit is placed in the glove to allow insertion of the beak and nostrils. The mask components should be sterilized between patients.

## Diseases

### Liver Disease

Toucans are frequently diagnosed with iron storage disease, liver cirrhosis and chronic acute hepatitis (Figure 47.5). They are among the species of birds most susceptible to iron storage disease.<sup>14,21,30,33,34,35</sup> Primary iron storage disease is generally considered to be of hereditary origin, while secondary disease occurs from exposure to toxic levels of iron, anemia or other factors (see Color 20).<sup>23</sup> It remains unclear whether hemochromatosis in toucans is caused by hereditary factors, excess dietary iron or a defect in iron metabolism. There does seem to be some species predisposition, with Toco Toucans being particularly susceptible.

Studies have shown that birds of paradise absorb 90% of their dietary iron intake, while humans absorb only 10% of their dietary iron.<sup>10</sup> Studies on the efficiency of dietary iron absorption in toucans have

not been performed. Based on the frequency of iron storage disease in a presumably genetically diverse group of birds, it is likely that an efficient iron absorption process plays some role in the development of iron storage disease.

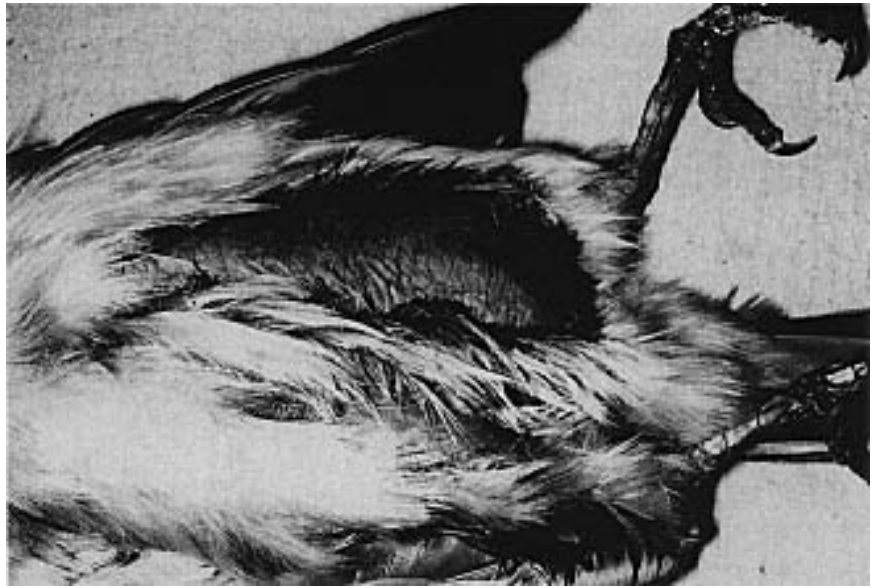Toucans with hemochromatosis may die acutely with no premonitory signs or can develop clinical signs, including emaciation, dyspnea and abdominal enlargement (ascites). Affected birds typically have an enlarged, yellow liver with ascites (see Color 20). Histologically, iron deposits are most frequently identified in hepatocytes and Kupffer cells, but may also be demonstrated in the spleen, renal tubular epithelium, lung, pancreas and intestines.<sup>35</sup> Definitive diagnosis requires the confirmation, with a Prussian blue stain, of excess iron in affected tissues or toxicologic analysis of liver tissue.<sup>39</sup>

Previously, an antemortem diagnosis of iron storage disease was made by measuring total serum iron, the total iron binding capacity (TIBC) and by taking a liver biopsy for histologic evaluation.<sup>33,35</sup> More recently, the same author surveyed 24 clinically normal birds and found bile acids, serum chemistries and hematology values within the normal reference in-

tervals. Liver biopsies from these birds showed histologic evidence of hemochromatosis, and toxic levels of iron were above the reported normal of 100-300 ppm.<sup>37</sup>

A low iron diet (< 150 mg/kg) and weekly phlebotomies to remove a blood volume equivalent to one percent of body weight have been suggested as methods to prevent hemochromatosis in Ramphastids with high serum iron levels.<sup>34</sup> Iron chelating agents have also been suggested as a method of treatment.<sup>33,35</sup>

Toucans do not frequently breed in captivity.<sup>2,4,17,22</sup> Because the liver is critical in the formation of yolk, it is possible that the frequency of hepatic-related problems in toucans directly affects their ability to reproduce.



**FIG 47.5** Ascites secondary to iron storage disease, liver cirrhosis and chronic active hepatitis is one of the most common clinical presentations in toucans. In this case, a toucanet from a breeding aviary was found dead in its enclosure. The bird had a severely distended abdomen. Fluid collected by abdominocentesis at necropsy was characterized as a transudate and there was no bacterial growth. The liver was enlarged and pale-orange. The histologic diagnosis was hemachromatosis.

### Infectious Diseases

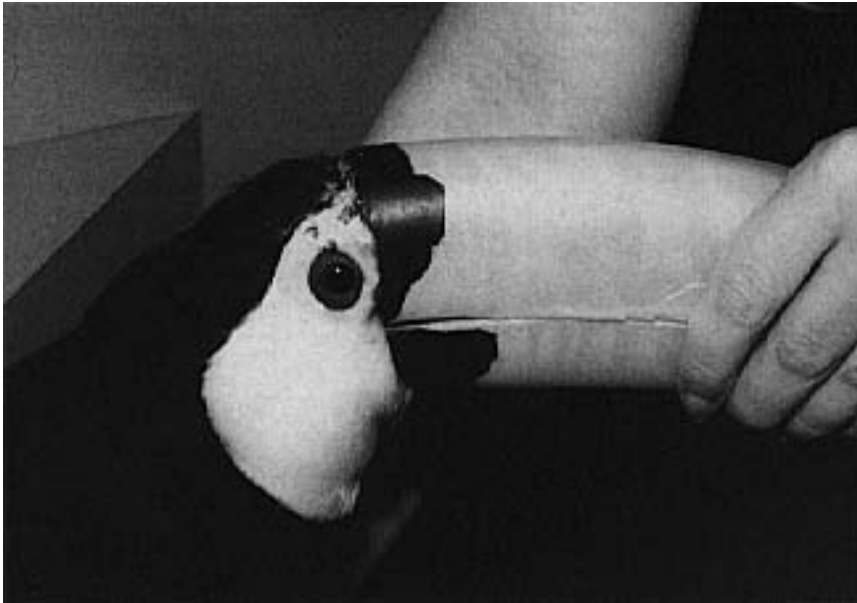
The normal aerobic and microaerophilic microflora of clinically normal toucans include *Escherichia coli*, *Staphylococcus* spp. and *Streptococcus* serotype D. These organisms were detected in the cloaca of 90% of 53 asymptomatic toucans representing five different species.<sup>6</sup> *Klebsiella pneumonia* was recovered from 50% of the clinically normal Red-billed and Plated-billed Mountain Toucans examined in one study. Birds from aviaries with good hygiene had fewer gram-negative bacteria than birds from less well maintained facilities. However, the fact that pathogenic gram-negative bacteria were commonly recovered from normal birds suggests that toucans are able to withstand colonization of the gastrointestinal tract by these bacteria better than are psittacine birds. Because gram-negative pathogens are frequently recovered from clinically normal Ramphastids, antimicrobial therapy should be considered only in patients with high concentrations of these bacteria, especially when they are demonstrating clinical signs of disease.

Avian pseudotuberculosis (*Yersinia pseudotuberculosis*) has been documented as a cause of acute death following a brief period of lethargy in toucans.<sup>3,4,7,8,16</sup> Infections are most frequently associated with a rapid bacteremia and peracute death. Postmortem findings include pneumonia, hepatomegaly and

splenomegaly. The enlarged liver and spleen are generally covered with numerous raised, white-to-yellow-orange foci (see Color 20).<sup>7</sup> Chronic debilitating infections have also been defined with *Y. pseudotuberculosis*. In these cases, bacteremia results in formation of granulomas in numerous parenchymatous organs.

It has been suggested that *Y. pseudotuberculosis* may cause dark-green or black discoloration of the orange portion of a toucan's bill, but the involvement of this bacteria in causing these lesions has not been confirmed.<sup>35</sup> In one study, *Y. pseudotuberculosis* was not isolated from the cloacal contents of 53 clinically normal toucans representing five species.<sup>6</sup> Small rodents, such as mice and rats, which normally are part of the toucan diet, are known to carry *Y. pseudotuberculosis* and may serve as a reservoir for infection.<sup>11</sup> The aviary should be rodent-proof, and only laboratory-raised mice and rats should be offered as food items.

An experimental *Y. pseudotuberculosis* vaccine appears to be clinically effective in reducing the prevalence of infections. All newly arriving toucans, tucanos and hornbills in a bird facility that normally experienced loss from *Y. pseudotuberculosis* were vaccinated with the experimental vaccine. A reduction in the morbidity and mortality in this group was evident.



**FIG 47.6** Toco Toucan with a chronic dermatitis. Cytology of skin scrapings from the wounds indicated a mixture of bacteria and fungi.

A pet male Toco Toucan that was housed indoors died following a one-day history of anorexia. The bird had acute nephrosis, and *Aeromonas hydrophilia* was recovered from the heart and liver. The source of bacterial infection was undetermined.<sup>27</sup> A three-year-old female Toco Toucan was diagnosed with *Mycobacterium* sp. Clinical abnormalities were limited to lethargy, poor feather formation and an enlarged abdomen. Necropsy findings included a swollen and congested liver, spleen and kidney. The intestinal wall was thickened, and the lumen was dilated and filled with fluid. In most species, mycobacterium infections tend to induce localized infections that result in the formation of discrete granulomas. In contrast, mycobacterium infections in psittacine birds and toucans are usually diffuse.<sup>32</sup>

#### Mycotic Diseases

A group of Toco Toucan neonates was diagnosed with corneal ulcers caused by *Candida* sp. Some of the affected birds had secondary bacterial infections. A combination of IV and topical amphotericin B as well as topical gentamicin ophthalmic solution resolved the ulcers. Scar formation was common (Figure 47.6).<sup>20</sup>

Acute deaths caused by *Penicillium griseofulum* were reported in a group of toucanets. Affected birds had a pale-green mold that was visible in the trachea, abdominal air sacs and lungs.<sup>1</sup>

Ergotism was suspected in a group of Keel-billed Toucan neonates being fed a kitten chow diet. Constrictive lesions occurred to multiple digits in the neonates. The most severely affected chick died. Changing the diet and initiating antifungal therapy prevented any further problems in the other neonates.

#### Viral Diseases

Newcastle disease virus was isolated from 3 of 48 toucans tested in a quarantine station.<sup>28</sup> A herpesvirus was recovered from a mature female toucan that died following a brief episode of depression and inappetence. Severe necrotizing hepatitis with intranuclear inclusion bodies in the spleen and liver were the principal histologic lesions. The toucan had been exposed to several macaws that died from herpesvirus five days before clinical signs developed in the

toucan. The herpesvirus isolated from the toucan did not react with Pacheco's disease virus-specific antibodies, suggesting that the isolate from the toucan was a serologically distinct herpesvirus. The bird was also diagnosed with chlamydiosis using the direct fluorescent antibody test of impression smears from the liver and spleen.<sup>5</sup>

#### Parasites

Three species of *Plasmodium* (*P. huffi*, *P. nucleophilum tucani* and *P. rouxi*) have been documented in toucans. High levels of *P. huffi* usually result in death. The other species have been associated with mild to subclinical infections in Swanson's Toucans, Sulphur-crested Toucans, Collared Aracaris, White-throated Toucans and Plate-billed Mountain Toucans.<sup>24,25</sup>

Fluke eggs and numerous giardia were found in the feces of a Red-bellied Toucan with loose droppings that contained undigested food. Metronidazole resolved the giardia infection in four days but had no effect on the flukes. Treatment with praziquantel (10 mg/kg) IM daily for three days followed by the same dose orally daily for 11 days was effective in stopping the passage of fluke eggs.<sup>12</sup>

Giardia is frequently identified in fecal samples collected from asymptomatic toucans. Currently, no clinical disease has been associated with these infections. However, toucans could serve as a reservoir for

this parasite and expose other avian species housed in the same facility. Ascarids, coccidia and capillaria are other parasites frequently encountered in toucans. These infections are treated in a manner similar to those described for psittacine birds (see Chapter 36).<sup>35</sup>

Subclinical infections with ventricular nematodes have been documented in toucans that were housed in enclosures once occupied by finches (the nematodes' natural host).<sup>35</sup> A subclinical infection with a diurnal microfilaria of an undetermined genera was documented in a Swanson's Toucan.<sup>24</sup>

### Metabolic Diseases

Idiopathic diabetes mellitus is frequently diagnosed in toucans. Weight loss, glucosuria (1 mg/dl), hyperglycemia (700 mg/dl often occur), polyuria and polydipsia are frequent clinical findings. The frequency with which this disease occurs suggests that the etiology is related to management or diet rather than genetic defects. Pancreatic islet cell tumors and hypothyroidism have also been suggested as causes for diabetes mellitus in toucans.<sup>35</sup>

Protamine zinc insulin (0.1 to 0.5 units BID) has been suggested as a possible treatment.<sup>35</sup> However, maintaining proper blood glucose in toucans with insulin is difficult. Long-term therapy is generally associated with pancreatic atrophy, which causes pancreatic exocrine insufficiency, eventually leading to death. Toucans also develop rapid tolerance to insulin, making proper administration difficult. In a study involving three normal adult Toco Toucans, it was determined that glucagon suppression did not occur following glucose challenge, suggesting that toucans metabolize glucose differently than do other birds.<sup>26</sup>

A toucan being fed a fruit and dog food kibble diet was found to have diabetes mellitus with a blood glucose level of 1587 mg/dl. Changing the diet to a 100% formulated diet<sup>d</sup> supplemented with prozyme reduced the blood glucose level to 365 mg/dl, suggesting this bird's diabetes was dietary related.<sup>26</sup>

### Products Mentioned in the Text

- Bird of Paradise Diet, Ziegler Bros. Inc., Gardners, PA (iron content 77 ppm)
- Harrison's Bird Diets, Pawnee City, NE (iron content 65 ppm)
- Science Diet, Hill Pet Nutrition Inc., Topeka, KS (iron content 100 ppm)
- Kaytee Softbill Diet, Green Bay, WI (iron content 80 ppm)

### References and Suggested Reading

- Aho R, Westerling, et al: Avian penicilliosis caused by *Penicillium griseofulvum* in a captive toucanet. *J Med & Vet Mycology* 28(5):349-354, 1990.
- Berry RJ, Coffey B: Breeding the sulphur-breasted toucan (*Ramphastos s. sulfuratus*) at the Houston Zoo. *Intl Zoo Yearbook* 16:108-110, 1976.
- Borst GH, et al: *Yersinia pseudotuberculosis* in birds. *Tijdschrift voor Diergeneeskunde* 102(2):81-85, 1977.
- Branch S: Breeding and handrearing toucans. *Assoc Avian Vet Today* 1(4):171, 1987.
- Büngener W: Tukane und Arasaris. *Die Gefiederte Welt* 113(3):73-76, 1989.
- Charlton BR, et al: Herpes viral hepatitis in a toucan. *Avian Dis* 34(3):787-790, 1990.
- Cornelissen JMM, et al: Cloacal microflora of healthy hornbills, toucans and aracaris. *Proc 1st Conf Europ Assoc Avian Vet*, 1991, pp 453-460.
- Dhillon AS, Shafar D: *Yersinia pseudotuberculosis* infection in two toucans and a turaco. *Proc 1st Intl Conf Zool & Avian Med*, 1987, pp 37-38.
- Dhillon AS, Schaberg DM: Pseudotuberculosis in toucans. *Proc 73rd Ann Meet Poultry Sci Assoc. Poul Sci* 63(suppl 1):90, 1984.
- Douglass EM: Diabetes mellitus in a toucan. *Med Vet Pract* 62(4):293-295.
- Frankenhuis MT, et al: Iron storage in livers of birds of paradise. *Proc 2nd Eur Symp Avian Med & Surg*, 1989, pp 92-95.
- Gerlach H: Bacterial diseases. In Harrison GJ, Harrison LR (eds): *Clinical Avian Medicine and Surgery*. Philadelphia, WB Saunders Co, 1986, pp 434-453.
- Giddings RF: Treatment of flukes in a toucan. *J Am Vet Med Assoc* 193(12):1555-1556, 1988.
- Gould J: A monograph of the Ramphastidae or family of toucans, London, 1837.
- Griner LA: Order Piciformes. In Griner LA (ed): *Pathology of Zoo Animals*. San Diego, Zoological Society of San Diego, 1983, pp 246-250.
- Haffer J: Avian Speciation in Tropical America. 1974, pp 179-312.
- Gutknecht P: Pseudo-tuberculose chez des toucans a bec carene (*Ramphastos sulfuratus*). *Proc Diseases of Zoo Animals XIVth Intl Symp*, Wrocław, 1972, pp 85-88.
- Hofner J: Hybrid Ramphastos toucans in captivity. *J Ornithol*, 119(2):233-234, 1978.
- Höfling E, Gase JP: Biomécanique du crâne et du bec chez Ramphastos (*Ramphastidae*, Aves). I. Descriptions des éléments anatomiques. *Gegenbaurs morph Jahrbuch* 130(1):125-147, 1984.
- Höfling E, Gase JP: Biomécanique du crâne et du bec chez Ramphastos (*Ramphastidae*, Aves). II. Analyse des conditions du mouvement du bec. *Gegenbaurs morph Jahrbuch* 130(2):235-262, 1984.
- Karpinski IG, Clubb SI: Further investigations into the ocular problems of caged birds. *Proc Assoc Avian Vet*, 1985 pp 101-108.
- Kincaid AL, Stoskopf MK: Passerine iron overload syndrome. *Zoo Biology* 6:79-88, 1987.
- Longo J: Breeding the toucan. *Proc Assoc Avian Vet*, 1989, pp 248-249.
- Lowenshine, LJ: Nutritional disorders of birds. In Fowler ME (ed): *Zoo and Wild Animal Medicine* 2nd ed. Philadelphia, WB Saunders Co, 1986, pp 204-205.
- Manwell RD, Sessler GJ: Malaria parasites of toucans. *J Protozool* 18(4):570-574, 1971.
- Manwell RD, Rossi GS: Blood protozoa of imported birds. *J Protozool* 22(1):124-127, 1975.
- Murphy J: Diabetes in toucans. *Proc Assoc Avian Vet*, 1992 pp 165-170.
- Panigrahy B, et al: Unusual disease conditions in pet and aviary birds. *J Am Vet Med Assoc* 178(4):394-395, 1981.
- Pearson GL, McCann MK: The role of indigenous wild, semidomestic, and exotic birds in the epizootiology of velogenic viscerotropic Newcastle disease in Southern California. *J Am Vet Med Assoc* 167(7):610-614, 1975.
- Phalen DN, et al: The avian urinary system: Form, function, diseases. *Proc Assoc Avian Vet* pp 44-57, 1990.
- Spalding M, et al: Hepatic encephalopathy associated with hemochromatosis in a toucan. *J Am Vet Med Assoc* 189(9):1122-1123, 1986.
- Stresemann J: *Handbuch der Zoologie*, 7de band, 2 teil, Sauroptadia: Aves. Walter de Gruyter und Co, Berlin und Leipzig, 1934.
- Van Der Heyden N: Avian tuberculosis: diagnosis and attempted treatment. *Proc Assoc Avian Vet*, pp 203-213, 1986.
- Worell A: Phlebotomy for the treatment of hemochromatosis in two sulphur-breasted toucans. *Proc Assoc Avian Vet*, 1991, pp 9-14.
- Worell A: Serum iron levels in Ramphastids. *Proc Assoc Avian Vet*, 1991, pp 120-130.
- Worell A: Management and medicine of toucans. *Proc Assoc Avian Vet*, 1988, pp 253-261.
- Zscheile D, Boeters E: Prothetische Versorgung eines Tukanschnabels. *Zoologische Garten* 50(5):353-357, 1980.
- Worell A: Further investigation in Ramphastids concerning hemochromatosis. *Proc Assoc Avian Vet*, 1993, pp 98-107.